

GROSS NECROPSY REPORT

SPECIES *Tursiops truncatus* **FIELD NUMBER** 47IMMS030311 **DATE** 3/4/11

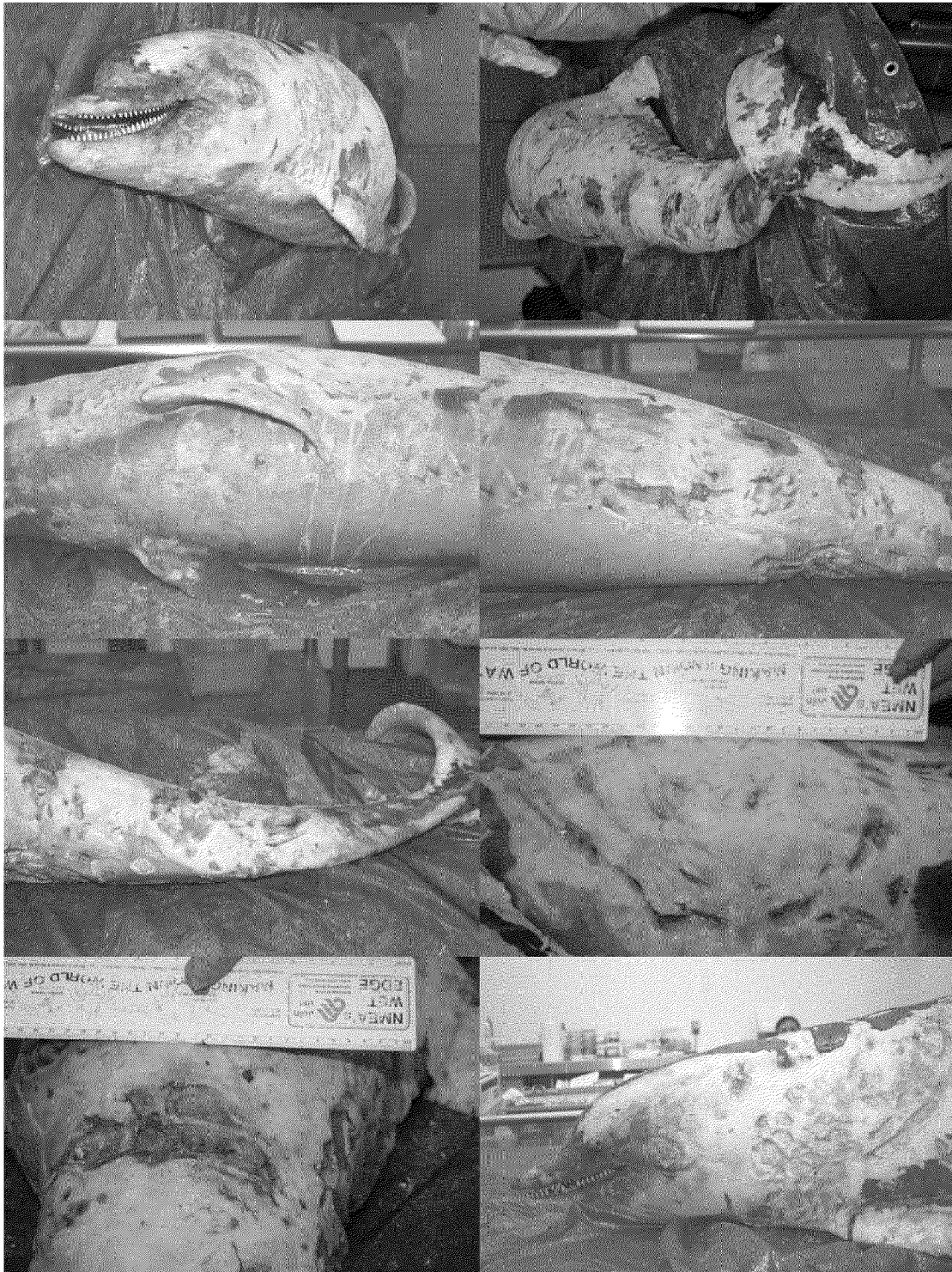
LOCATION 75 meters South of Winward Pointe Condos, Orange Beach, AL
LAT30.26379 **/LONG** -87.601741

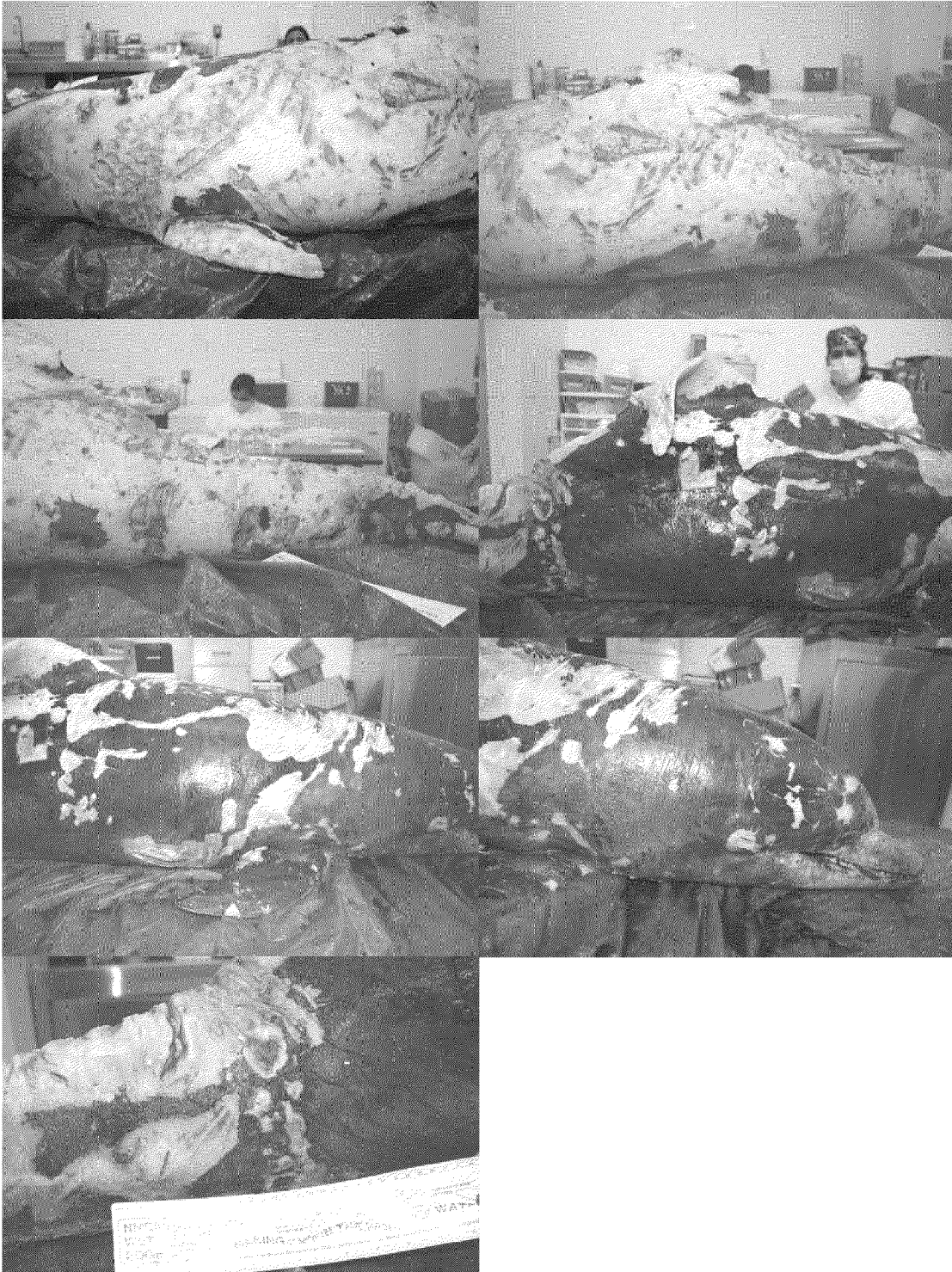
GENDER Male **TL** 183 cm **COND** 3 **WEIGHT** 91 kgs (estimated)

HISTORY: Found dead on beach. Singe stranded animal. Human interactions- CBD. No gear found on the animal or collected. Cadaver taken to IMMS, Gulfport, MS for necropsy

NECROPSY

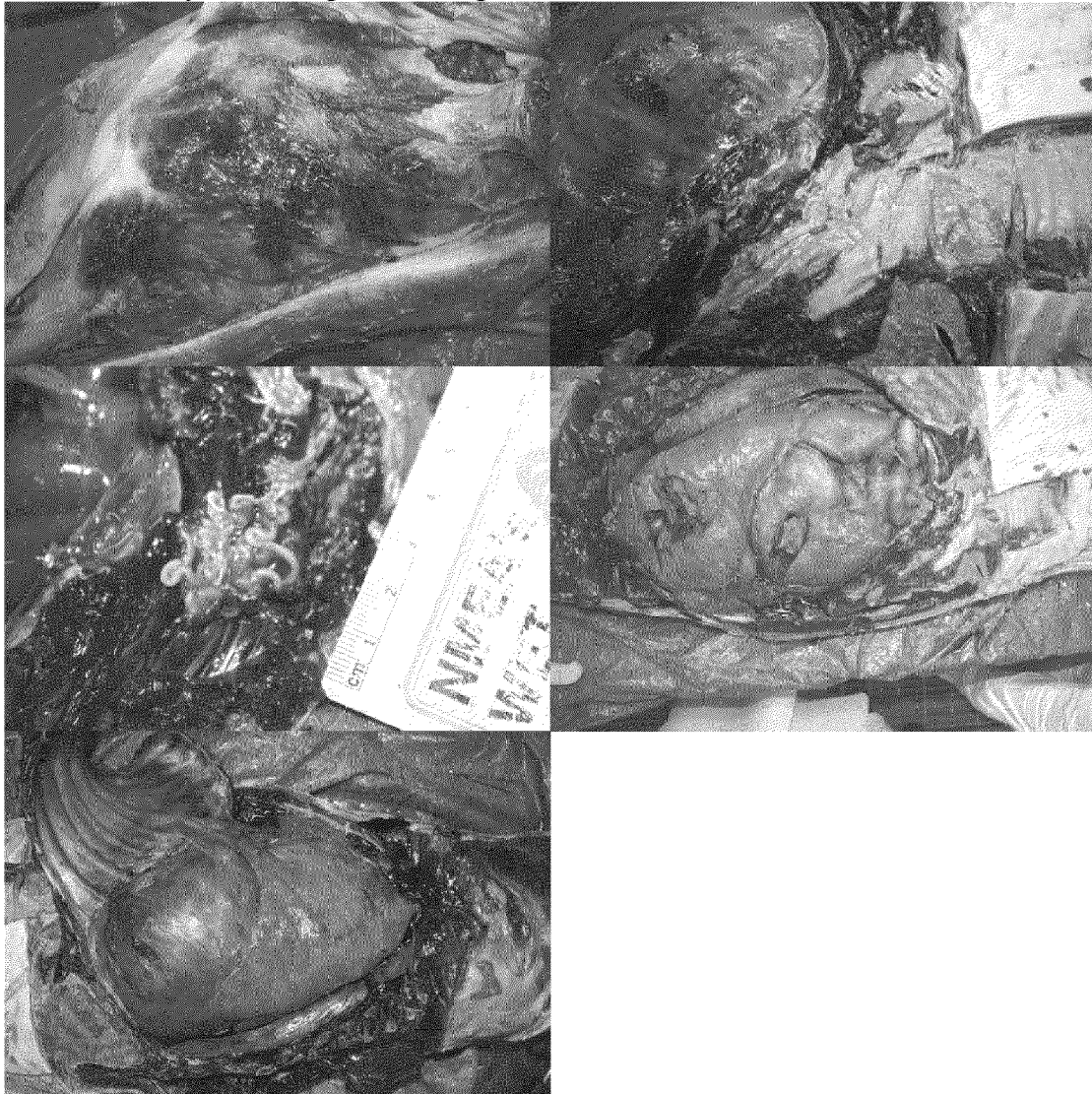
EXTERNAL EXAM: Majority of left side had skin missing. Multiple semicircular (possible shark bite) lesions on the right side penetrating to muscle layer. Multiple irregular shaped lesions, some semicircular on the peduncle, penetrating to muscle layer. 5 linear lesions on the left lateral peduncle penetrating to muscle layer. Teeth- 23 upper L jaw, 24 lower L jaw. Mal-occlusion on left jaw. Blood coming out of mouth. Left eye is ruptured. Right eye ruptured. Loss of skin on lateral left pectoral fin. Teeth fragile, breaking easily on extraction. Penis necrotic and protruding. Loss of skin on majority of dorsal and ventral flukes. Tongue is greenish. Sub-blubber tissue appears greenish. Puncture wound w/linear scrape on dorsal left fluke. Coalescing irregular circular and linear loss of skin on right side. Multiple conspecific rake marks on dorsal area starting at neck and extending to dorsal fin. No skin left on dorsal fin. Dorsal fin is flapping over to right side. Skin present on top of right pectoral fin. Conspecific scarred rake marks on right pectoral fin ventral aspect. Multiple linear and circular lesions on right side extending from dorsal peduncle to ventral area. Possible rope marks, extending all the way across peduncle.





INTERNAL EXAM: left shoulder joint capsule greenish. Hemorrhage and edema in sub-blubber in neck area. Blubber adhering to the SQ fascia along the lateral thoracic area. Serosanguineous fluid in thoracic cavity. Lungs dark red and light red mottled generalized. Diaphragm is dark red/pink with linear discolorations. Parasites- Several 2 mm serpentine light tan colored parasites found in sub-blubber fascia on left lateral

abdominal body wall. Lung- hemorrhagic areas around the bronchi.



BLUBBER: Thickness in front of dorsal fin- dorsal-2.0 cm, lateral- 1.0 cm.

MUSCULOSKELETON

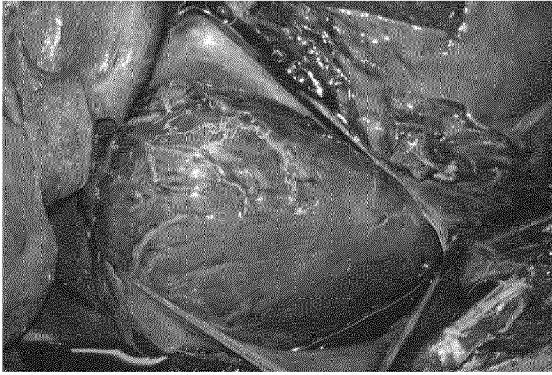
Axial Muscle: Parasites- Several 2 mm serpentine light tan colored parasites found in sub-blubber fascia on left lateral abdominal body wall.

Axial Skeleton: No fractures found.

Ribs & Sternum: No fractures found.

CIRCULATORY SYSTEM

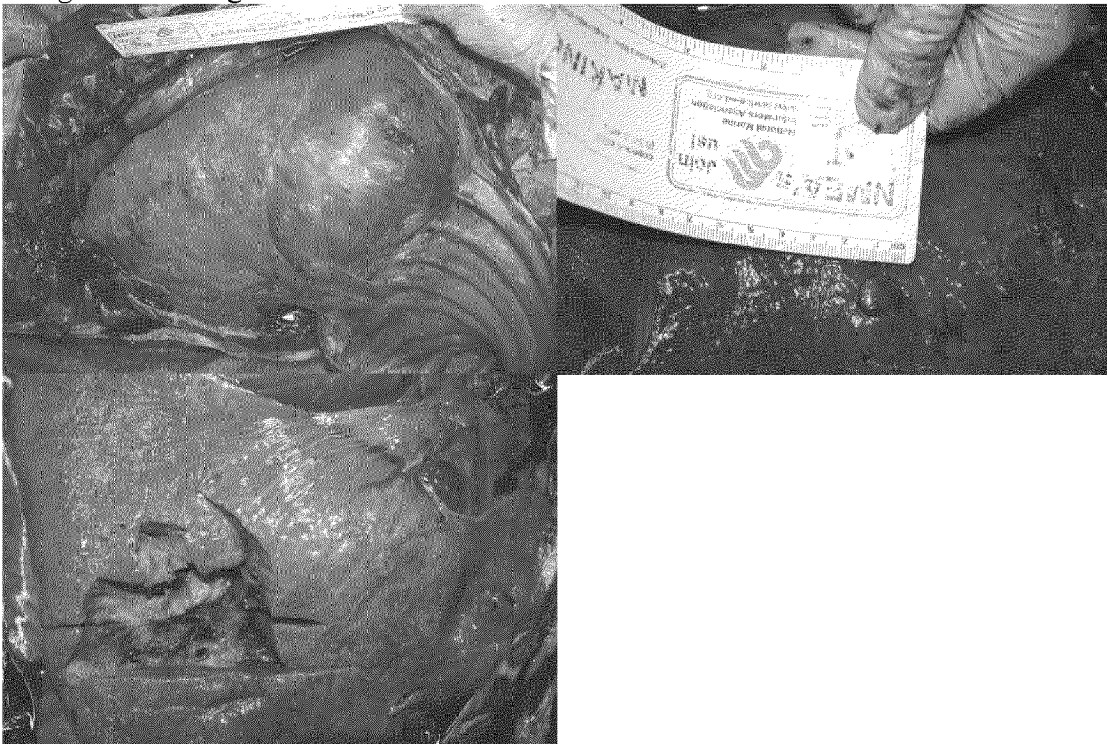Heart: All chambers, valves and heart vessels appeared normal. Blood in pericardial sac.



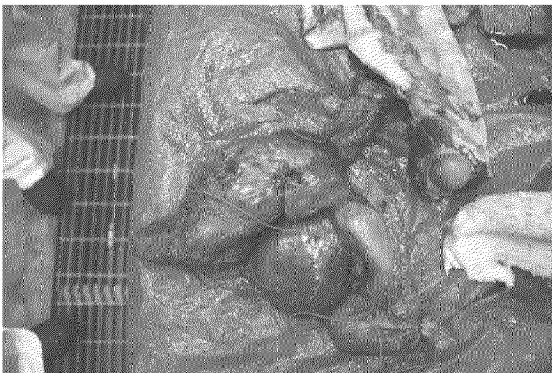RESPIRATORY SYSTEM

Blowhole: Patent and no parasites found.

Lungs: Hemorrhagic around bronchi.



DIGESTIVE SYSTEM



Esophagus: No obstruction, ulcers or food found

Fore Stomach: Not examined. Collected entire contents for future evaluation.

Main Stomach: Not examined. Collected entire contents for future evaluation.

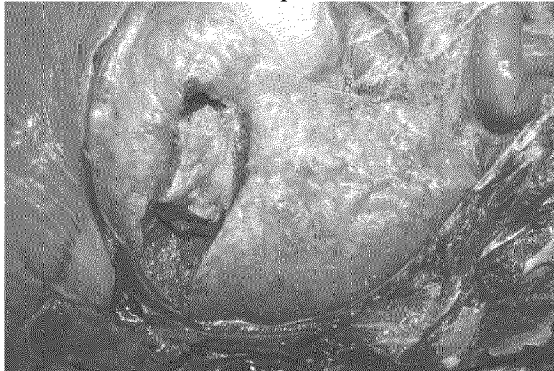Pyloric Stomach: Not examined. Collected entire contents for future evaluation.

Intestine: No ulcers or parasites found.

Describe food-stuffs found in GI Tract: Not examined.

Describe parasites found in GI Tract: Not examined.

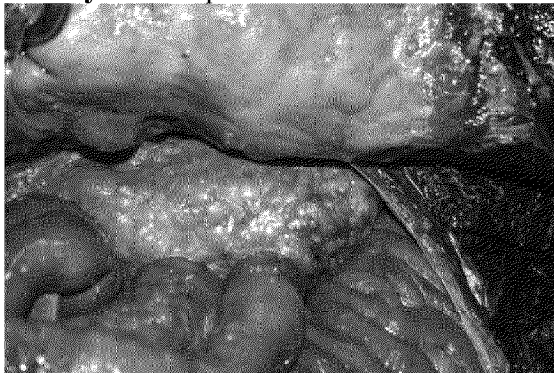
Liver: Soft, has subcapsular air, dark red color.



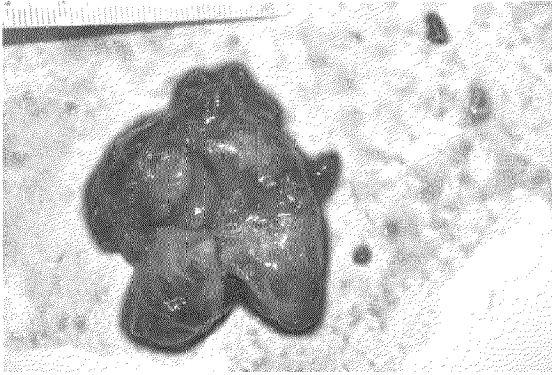Pancreas: Subcapsular air, light pink

URINARY SYSTEM

Kidneys: Subcapsular air. No stones found. Normal architecture on gross examination.



Adrenals: Dark reddish brown



Urinary Bladder: No stones found, normal mucosa.

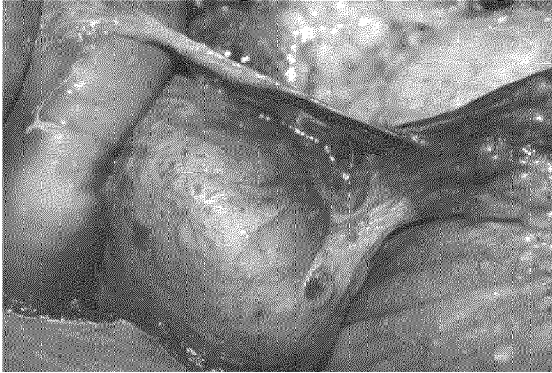ENDOCRINE & HEMOLYMPHATIC SYSTEMS

Thymus: Not present.

Thyroid: Dark red.

Pituitary: Autolyzed

Spleen: Whitish capsule with purplish spots. Dark red medulla.




Lymph Nodes: Prescapular lymph nodes are necrotic. Pelvic ln were blackish red.

REPRODUCTIVE TRACT: Prostate normal size for this age. Right testis- 8 x 1.5 x 1.8 cm.

CENTRAL NERVOUS SYSTEM

Brain: Congestion on left cerebrum. Section of cerebellum visible on cutting into skull- possible herniation.



Spinal Cord: Blood in spinal canal.

HEAD

SENSORY ORGANS

Eyes: Both eyes ruptured.

Ears: Appeared grossly normal.

CONCLUSIONS:

Carcass Disposition:

CAUSE OF DEATH FROM FIELD DETERMINATION:

This report was generated by: Dr. Connie Chevis

TISSUES COLLECTED

Virology: NOAA, frozen
Spleen

Biotoxins: NOAA. Frozen
Feces
Urine
Liver

Life History: NOAA , Frozen
Stomach, whole

Frozen: IMMS X 6
Blubber
Muscle
Liver
Teeth
Kidney-L
Urine
Skin

Feces
Blood

Histo (10% Buffered Formalin): DROT x 1, IMMS X2

Lung
Heart- 4mm punch biopsies- R, L Atrium, R,L Ventricle.
Thyroi 3/7/11
Spleen
Liver
Kidney-L
Adrenal-L
Muscle
Lymph nodes- suprascapula, pelvic
Lung lesion
Broken teeth- 3

Hydrocarbon: X2

Liver
Lung
Thoracic fluid X 2
Blubber
External swab

Viral: Dr. Romero

Lung
Thoracic fluid
Prescapular ln

MHG- Bacterial and fungal

Thoracic fluid- Vibrio alginolyticus

Parasites

Left lateral fascia under blubber x 2

PHOTOS/VIDEO: Yes/No

ASSOCIATED DATA SHEETS: Level A Data Form, Delphinid Specimen record, IMMS MM
Necropsy tissue form, Northern Gulf UME Sample Collection Check List, NOAA Chain of
custody record.