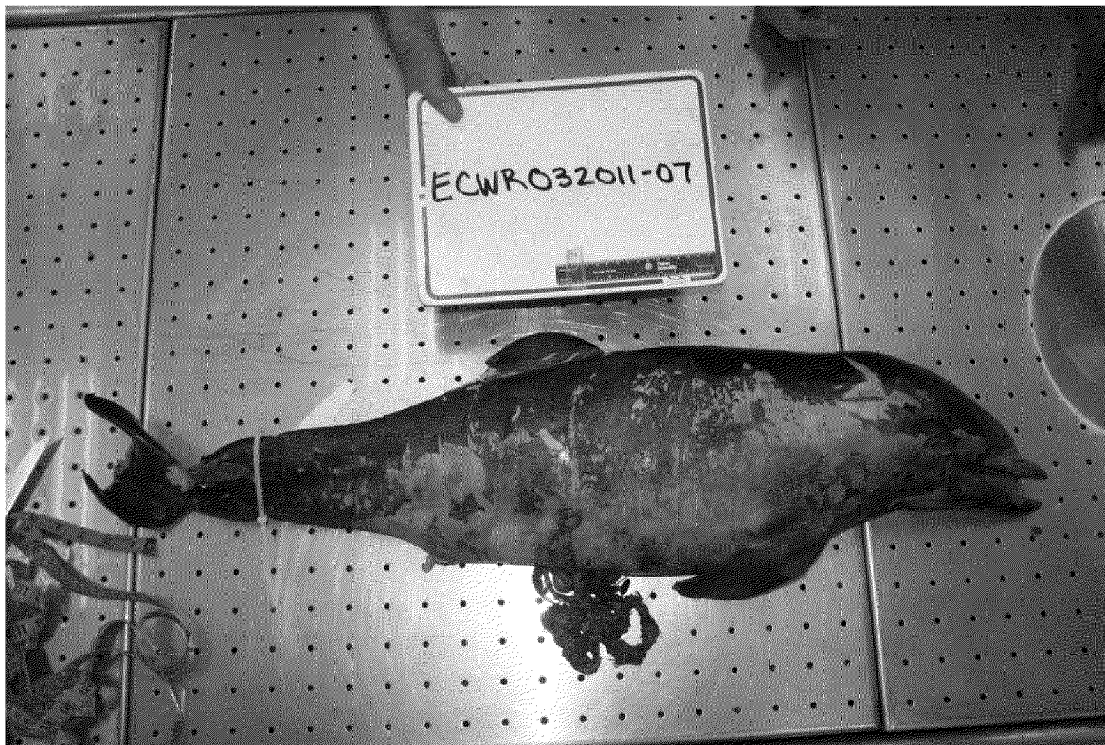


**GROSS NECROPSY REPORT**

**SPECIES** *Tt*      **FIELD NUMBER** ECWR032011-07      **DATE** July 21, 2011  
**LOCATION** Pensacola, FL      **LAT/LONG** 30.31213/-87.45406  
**SEX** M      **TL** 97 cm      **COND** 4      **WEIGHT** N/E



**ECWR032011-07 *Tt***

**GROSS NECROPSY**

A 97 cm total length, perinatal male *Tursiops truncatus* is presented dead July 21, 2011 in very poor post mortem (code 4) and moderate body condition. The animal is moderately fleshed. There are no stomach or colonic contents. Segments of small intestine protrude from the umbilicus. Rostral follicles are noted and the dorsal fin is folded. The ductus arteriosus is patent and representative portions of lung partially sink in formation.

**CONCLUSIONS**

Gross evaluation of this animal was impeded by marked post mortem decomposition. There were no apparent lesions within the carcass which may account for the loss of this animal. The extruded segments of bowel through the umbilicus is presumably due to putrefaction.

GROSS FINDINGS

1). Carcass: Open-post mortem decomposition

TISSUE DISPOSITION

Skin and mandible, life history

Brain, adrenal gland and lung, virology

Head, radiology

Lung, histology

Carcass remains, archived

Gross photos